

# STRUMA NODOSA / THYROID NODES



SCHILDDRÜSEN-LIGA  
DEUTSCHLAND E.V.

Umbrella organisation of self-help groups for thyroid  
sufferers and their relatives

Member of the Thyroid Federation International (TFI)



*Just a minute!*

Sleep disturbances  
Fits of rage  
Depressions  
Fatigue  
Increase in weight  
Nervousness

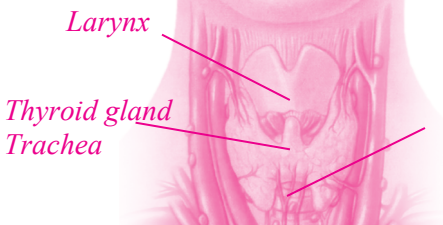
## *The thyroid gland*

The thyroid is a small hormone gland many people are not aware of. It is located in front of the larynx and can normally not be felt. Although it is of paramount importance, it is not felt until it attracts attention by its rebellious behaviour.

**Together with you**, we will make sure that your thyroid remains peaceful.

**The Schilddrüsen-Liga** Deutschland e.V. has committed itself to bring thyroid experts and patients together around one table. The targets are the promotion of the knowledge about the diseases of the thyroid, its prevention, early detection and best possible treatment.

This also requires the cooperation of an **informed patient**. In addition, the **Schilddrüsen-Liga Deutschland e.V. wishes to support** patients and their relatives in the foundation of self-help groups.



## *Struma nodosa / thyroid nodule*

Struma refers to the enlarged thyroid gland, nodus to its Latin origin and means node. Therefore, the struma nodosa diagnosis means a nodular change of the thyroid. Thyroid nodes are very frequent in Germany, with women somewhat more frequently affected than men. A distinction of the thyroid nodes is made in terms of their capability of producing thyroid hormones and thus hot and cold nodes. The nodes producing the thyroid hormone are also referred to as autonomous adenomas. Also, thyroid carcinomas are thyroid nodes, with the majority of thyroid nodules being benign.

Thyroid nodes may become conspicuous by complaints within the neck area. Often, they are identified as accidental findings during a thyroid ultrasound examination.

### **Causes:**

Normally, thyroid nodes are formed by an excessive growth of some thyroid cells, with the cause of the increased growth not being identifiable in individual cases. The probability that a nodular change in the area of the thyroid occurs is basically significantly higher in case of a iodine deficiency than in case of a sufficient iodine supply. One can say for certain that a hereditary predisposition encourages the formation of thyroid nodes since they often appear frequently in families. However, only a few genes which enlarge of the thyroid are known to date. A genetic study is not useful today. The

thyroid cysts can be regarded as a special form of thyroid nodes. This is an accumulation of liquid in the thyroid gland which can often be palpated as a node. Also, the cause of the thyroid cysts is still unknown to a large extent; it can be presumed that a disturbed adherence of the thyroid cells to one another and/or to the connective tissue which extends through the thyroid gland is of some significance for that.

### Symptoms:

Struma nodosa may have a variety of symptoms. A distinction is to be made between local symptoms, e.g. symptoms existing directly on the location of the node, i.e. in the neck area, and symptoms caused by a disturbed thyroid function.

Typical local symptoms are a sensation of pressure in the neck area; also, swallowing difficulties are possible if the node exerts pressure on the oesophagus or shortness of breath occurs if pressure is exerted on the trachea respectively. Whether or not these symptoms exist does not only depend on the size and position of the nodes but also on the growth rate. Basically, the probability of symptoms is the larger the faster a node grows. A special form of the thyroid cyst may cause an acute bleeding into the cyst and thus intense pains in the neck area since the pressure in the cyst is significantly increased. Many patients with small thyroid nodes have no complaints at all, and even some patients with very large thyroid nodes which grow slowly may be asymptomatic.

A disturbed thyroid function (hyperthyroidism) can only exist with nodes producing hormones, i.e. hot nodes. Hot nodes produce too much thyroid hormone, and this thyroid hormone production can no longer be subject to normal regulation of the body, probably resulting in an accelerated heartbeat (palpitations), increased propensity to sweat, weight loss, hair loss, heaped and/or thin bowel movements, increased nervousness and sleep disturbances.

### **Diagnostics:**

Today, an examination of the thyroid node cannot go without an ultrasound examination. The ultrasound examination allows the identification and an accurate measurement of the exact location of the node. In addition, the tissue structure of the node can be assessed, with a distinction made between low-echo, echoic and high-echo nodes. Also, thyroid cysts, i.e. liquid-filled cavities in the thyroid gland, can normally be identified simply by an ultrasound examination.

Whether or not a node produces hormone, cannot be determined by the ultrasound examination. Different criteria allow a certain judgement as to whether or not a thyroid node is a benign or malignant change. This distinction by a sole ultrasound examination is not possible either.

A thyroid scintigraphy can be used make a distinction between hot and cold nodes. To this effect, the patients are given an injection of a low-level radioactive

substance (technetium) into the thyroid gland and thus the acceptance in the thyroid node can then be determined. Hot nodes absorb particularly much of this substance, cold nodes show no or a significantly reduced absorption. Hot nodes are almost always benign with adults. However, problems may occur by the increased hormone production in the nodes if this triggers a hyperfunction. Conversely, the danger of a hyperfunction does not exist with cold nodes; however, a small part of the cold nodules may also conceal malignant thyroid findings. Therefore, cold nodes should normally be determined further by a tissue sample which can be obtained easily by the fine-needle puncture.

During the fine-needle puncture, a very thin needle is placed in the node through the skin under an ultrasound view to obtain cells from the node for a microscopic examination. The needles used for that are significantly thinner needles than used for a withdrawal of blood.

A supplementary examination of the thyroid hormones in the blood allows conclusions on the hormone production in the node; in case of hot nodes, this is absolutely necessary for the identification of a hyperfunction and an assessment of its extent. The determination of thyroid antibodies may provide information on an autoimmune thyroid disease, which can also be a nodular struma. The determination of the calcitonin tumour marker may sometimes be useful in case of cold nodes if a special form of thyroid carcinoma, the so-called C-cell carcinoma, is suspected.

## Therapy:

The therapy of the thyroid node depends on the existing or expected complaints. Therefore, the therapy may be dispensed with in case of small thyroid nodes which do not cause any complaints, in particular if the nodes are not within an enlarged thyroid gland. However, ultrasound examinations should regularly be performed to identify the growth tendency of the nodes since problems have to be expected in case of growing nodes. If the thyroid nodes are within an enlarged thyroid, an iodine deficiency can often be assumed so that the administration of iodine is meaningful, possibly in combination with a thyroid hormone as well.

This is not useful or even dangerous in case of hot nodes since the hyperfunction can be intensified by that. If hot nodes exist, the iodine therapy can eliminate these cells in a targeted manner. Also, this therapy significantly reduces the hot nodes. In case of very small nodes, this is not required in every case. If the thyroid values in the blood are inconspicuous and there are no complaints because of a hyperthyroidism, a therapy can often be dispensed with. Hot nodes may also be treated by injecting alcohol. To this effect, a thin needle is positioned in the node under ultrasound control and a small amount of alcohol is injected which, however, is somewhat painful. Formerly, this process was used more frequently since the waiting times for a radioiodine therapy were very long.

A thyroid surgery is required whenever a malignant thyroid node is suspected. Even if the complaints exist within the neck area and are caused by the thyroid nodes, a decision on a thyroid surgery will be made. The extent of the thyroid surgery depends on the ultrasound findings. If several nodes exist in the thyroid, the removal of large parts of the thyroid gland is also required. This is useful as well if the nodes already occur at an early age and the family is known for a high risk of a thyroid enlargement since then an increased risk for the occurrence of other nodes in the currently still normal thyroid tissues can be expected. In case of single or individual nodes it is often possible to remove the part of the thyroid affected by the nodes, leaving the rest of the thyroid as it is so that a sufficient amount of functional thyroid tissue is left and the intake of thyroid hormones otherwise required after the operation is not necessary.

As far as purely cystic thyroid changes are concerned, the treatment by a fine-needle puncture is often possible. To this effect, the liquid is removed from the thyroid by a needle.

Iodine + levothyroxine are mainly available for a medicative therapy of a nodular thyroid. In case of hot nodes as well as autoimmune thyroid diseases, an administration of iodine may adversely affect the progress of the disease. Therefore, a careful examination should always be made prior to the start of the therapy.



### Progress checks:

Regular ultrasound checks of the thyroid nodes are required in any case, and these checks should be made at shorter, e.g. 3 to 6-month intervals after the identification of a thyroid node. If no growth tendency of the nodes is identified over an extended period of time, the check intervals can be extended to comprise intervals of 1 to 2-YEARS.

If a therapy with thyroid hormone is conducted, an examination of the the thyroid levels in the blood is additionally necessary. In case of hot nodes, this should be done regularly independently of the therapy. Even after a thyroid surgery, ultrasound examinations can be performed once about 3 months after the operation to measure the extent of the remaining thyroid tissue exactly. If the entire thyroid was not removed, further ultrasound examinations are useful at approx. annual intervals to identify a new formation of nodes in time, if applicable.

After the radioiodine therapy, there is a risk of hypothyroidism so that regular checks in the laboratory are absolutely necessary in such a case. Also, ultrasound examinations must be performed after a radioiodine therapy to normally provide evidence of a significant reduction in the hot notes during the progress. A thyroid scintigraphy can be useful after a radioiodine therapy to identify the hormone production in the formerly hot node; however, this is not necessary in every case.

## *Laboratory values*

### **TSH:**

Thyroid Stimulating Hormone. This hormone is produced in the pituitary gland and controls the thyroid function.

### **T<sub>3</sub> or fT<sub>3</sub>:**

Triiodothyronine is a highly efficacious thyroid hormone. Approx. 10% of the thyroid hormone is released in this form in healthy persons. T<sub>3</sub> can be measured in the blood where the largest part of the hormone is bonded to the protein and serves as a hormone supply.

Also, the free hormone, i.e. the hormone not bonded to the protein, can be measured. Then, the laboratory findings often show fT<sub>3</sub>.

### **T<sub>4</sub> or fT<sub>4</sub>:**

Tetraiodothyronine, also called thyroxine. Approx. 90% of the thyroid hormone is released by the thyroid in this form. It is converted to the highly active T<sub>3</sub> takes partially place in the liver but also in other tissues where the thyroid hormone is needed.

### **TPO-AB and TG-AB:**

Thyroperoxidase antibodies and thyroglobulin antibodies. These are antibodies produced by the immune system and are directed against the thyroid protein thyroperoxidase or thyroglobulin. If these antibodies can be detected in the blood, this may indicate an autoimmune disease of the thyroid.

### **TRAB:**

TSH receptor antibodies. They are produced by the immune system, like TPO-AB and TG-AB. These antibodies are directed against the TSH receptor

and may activate or block it. TRABs can be detected in the blood of patients suffering from a Basedow thyroid disease.

**Thyroglobulin:**

This is a form of an accumulation of the thyroid hormone in the thyroid. This substance is produced by thyroid cells only. During the aftercare of patients suffering from a papillary or follicular thyroid carcinoma, this substance is measured in the blood for an early detection of a recurrence.

**Calcitonin:**

This is a hormone which is produced in a small number of thyroid cells which do not belong to the cells which actually produce the thyroid hormone. In case of a rare tumour form of the thyroid, the medullary thyroid carcinoma, this value is almost always elevated in the blood.

**Thyroid sonography:**

Ultrasound examination of the thyroid. This allows an exact measurement of the thyroid size, a judgement of the tissue structure as well as a detection and measurement of nodal changes and cysts.

**Thyroid scintigraphy:**

This process is used to generally inject a low-radioactive substance which accumulates in the thyroid. After approx. 20 minutes, the distribution of the substance in the thyroid can then be analysed. An accumulation is high where much iodine is absorbed, e.g in the bones which produce the thyroid hormone (hot nodes). Nodes which do not show any accumulation are referred to as cold nodes.

**Fine-needle puncture:**

A very thin needle is inserted into the thyroid through the skin to obtain some cells for a microscopic examination. In most cases, this examination is not more painful than a withdrawal of blood. In particular, cold nodes (see thyroid scintigraphy) should be punctured since they sometimes obscure thyroid carcinomas.



